

PennHIP Report

Referring Veterinarian: Dr Jane Ough

Clinic Name: South Wairarapa Veterinary Services

Email: jane.ough@swvets.co.nz

Clinic Address: 8 High Street South
Carterton 5713

Phone:

Fax:

Patient Information

Client: CASEY, NICKEY

Tattoo Num:

Patient Name: Matipo baccus Vito
#991003002459859

Patient ID: baccucasey

Reg. Name: MATIPO BACCUS VITO

Registration Num: 03082 2023

PennHIP Num: 206305

Microchip Num: 991003002459859

Species: Canine

Breed: LAGOTTO ROMAGNOLO

Date of Birth: 13 Apr 2023

Age: 17 months

Sex: Male

Weight: 26.5 lbs/12 kgs

Date of Study: 03 Sep 2024

Date Submitted: 02 Sep 2024

Date of Report: 09 Sep 2024

Findings

Distraction Index (DI): Right DI = 0.36, Left DI = 0.34.

Osteoarthritis (OA): **No radiographic evidence of OA for either hip.**

Cavitation/Other Findings: No cavitation present.

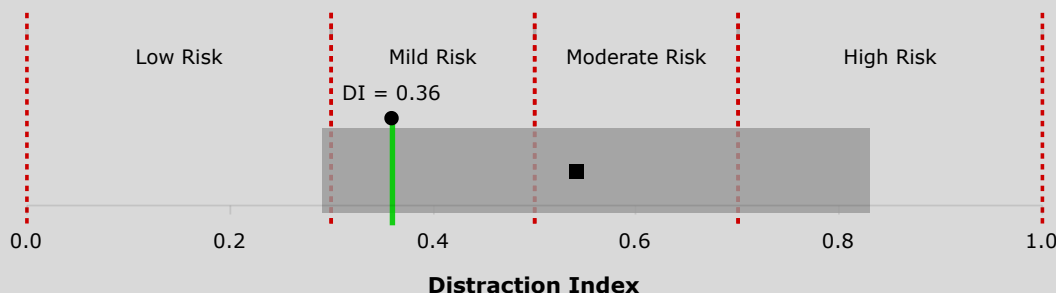
Interpretation

Distraction Index (DI): The laxity ranking is based on the hip with the greater laxity (larger DI). In this case the DI used is 0.36.

OA Risk Category: The DI is between 0.31 and 0.49. This patient is at mild risk for hip OA.

Distraction Index Chart:

LAGOTTO ROMAGNOLO



BREED STATISTICS: This interpretation is based on a cross-section of 654 canine patients of the LAGOTTO ROMAGNOLO breed in the AIS PennHIP database. The gray strip represents the central 90% range of DIs (0.29 - 0.83) for the breed. The breed average DI is 0.54 (solid square). The patient DI is the solid circle (0.36).

SUMMARY: The degree of laxity (DI = 0.36) falls within the central 90% range of DIs for the breed. This amount of hip laxity places the hip at a mild risk to develop hip OA. **No radiographic evidence of OA for either hip.**